

# SANSKRITI AYURVEDIC MEDICAL COLLEGE & HOSPITAL, CHHATA, MATHURA (U.P.)

INSTITUTE ID: AYU0503

Approved by Department of Ayush Govt. of India, New Delhi. Recognized by  
Central Council of Indian Medicine, New Delhi.

---

## THE DETAILS OF THE RESEARCH PUBLICATION DURING LAST ONE YEAR

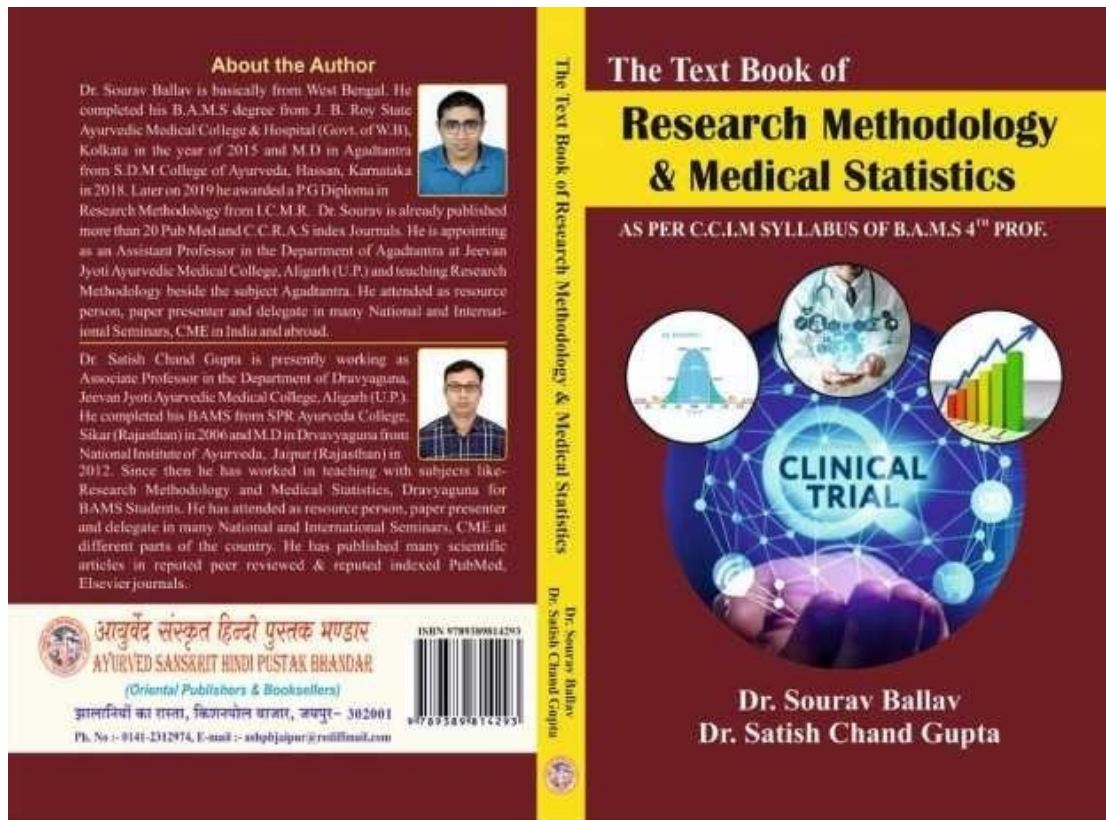
DR.SAYANTAN CHAKRABORTY, ASSISTANT PROFESSOR, DEPT. OF SHALYA  
TANTRA, SANSKRITI AYURVEDIC MEDICAL COLLEGE & HOSPITAL, MATHURA  
(U.P)

TITLE & JOURNAL DETAILS: SIRAVYADHANA IN PARIVARTIKA – A SCIENTIFIC  
REVIEW, INTERNATIONAL RESEARCH JOURNAL OF AYURVEDA & YOGA

AN INTERNATIONAL PEER REVIEWED JOURNAL FOR AYURVEDA & YOGA, ICV-70.44-  
ISRA-  
1.318  
VOLUME 4 ISSUE 5

ARTICLE PUBLISHED 31<sup>st</sup> MAY 2021

**BOOK PUBLISHED- THE TEXTBOOK OF RESEARCH METHODOLOGY AND MEDICAL STATISTICS as per CCIM syllabus of BAMS fourth prof..**



## A COMPREHENSIVE STUDY OF SURGICAL INCISIONS WITH SPECIAL REFERENCE TO TIRYAK CHEDA AND ITS APPLIED ANATOMY

Dr. E. R. Surabhi\*

Associate Professor Dept. of Rachana Sareera, Sanskriti Ayurvedic Medical College and Hospital, Chaata, Mathura, Uttar Pradesh 281401.

Article Received on  
12 November 2022,

Revised on 02 Dec. 2022,  
Accepted on 22 Dec. 2022,

DOI: 10.20959/wjpr20231-26789

### \*Corresponding Author

Dr. E. R. Surabhi

Associate Professor Dept. of  
Rachana Sareera, Sanskriti  
Ayurvedic Medical College  
and Hospital, Chaata,  
Mathura, Uttar Pradesh  
281401.

### ABSTRACT

*Acharya Sushruta* has described *Astavidha Shastrakarmas*, incisions being one among them. The type of incisions according to region has also been described. *Chedana* should be *Tiryak* at *Bhru* (eyebrow), *Ganda* (cheek), *Shankha* (temple), *Lalata* (forehead), *Akshiputa* (eyelid), *Ostha* (lip), *Dantaveshtaka* (gum), *Kaksha* (axilla), *Kukshi* (belly) and *Vankshana* (groin) region. Otherwise there is cutting of veins and ligaments, severe pain, delayed healing and appearance of polypus-like growth. The understanding of *Tiryak Chedana* is still vague and needs to be studied in depth. There are various types of surgical incisions indicated in modern surgery. So in light of Ayurvedic and Modern references the surgical incisions in the regions were *Tiryak Cheda* has been advised by *Acharyas* were compared and

assessed along with cadaveric dissection of these regions. From the present study it was observed that there is significant relation between the *Tiryak Cheda* explained by *Sushruta* to the surgical incisions being practiced now. The incisions advised by *Acharyas* mostly follow the pattern of relaxed skin tension line and produces lesser damage of beneath structures.

**KEYWORDS:** *Tiryak Cheda*, surgical incisions, dissection.

### INTRODUCTION

The history of trauma can be anticipated from the date, survival of the fittest. The surgical experience of the ancient age has been compiled systematically in *Sushruta Samhita*, which is a first documentation of its kind.<sup>[1]</sup>

Defining the anatomical site of the lesion is crucial if the physician is to resolve the problem effectively and compassionately. Therefore, a sound knowledge of anatomy is essential from the beginning of a modern medical education. The singular act of cadaveric dissection in Indian medical curricula brought about changes in the perception of body, health and illness.<sup>[2]</sup>

“Surgical incision is a cut in to body tissue or organ made during surgery with sharp instrument.” Incision must not only give ready and direct access to the anatomy to be investigated but also provide sufficient room for operation to be performed with minimum damage of constituent structures. An incision along the cleavage line will heal as a narrow scar, whereas one that crosses the line will heal as wide or heaped up scar.<sup>[3]</sup>

Acharya Sushruta has indicated types of incisions according to region for Bhedana karma and also clearly described the reason behind it.<sup>[4,5]</sup>

There are various types of surgical incisions indicated in modern surgery, so in light of most advanced knowledge of anatomy, region wise comparative study of the incisions of both the science was done and also a trial was made to emphasize the uses of ancient knowledge today.

## MATERIALS AND METHODS

Literary data were collected from, different classical texts, journals, internet, previous Thesis works etc.

Study was done to analyse the anatomical background of the regions where *Tiryak Cheda* has been mentioned by *Acharyas*.

Cadaver data was collected from dissection of 5 cadavers, carried out in the dissection hall of Alvas Ayurveda College, Moodbidri.

## METHODOLOGY

- Dissections of 5 cadavers were carried out
- Observations of underlying anatomical structures of each of the regions were *Acharyas* has advised *Tiryak Cheda* was done.
- Collected data was analyzed and discussed emphatically.
- Structurally well prepared and preserved cadavers were selected.

## Procedure

Detailed dissection of 5 cadavers was carried out. The cadavers were 5 male subjects, with an estimated age range of 56 to 80 years. All cadavers were preserved in a standard formalin/phenol/alcohol solution and routinely dissected under guidance. The dissection procedures were carried out as per Cunningham's Manual of Practical Anatomy.

In the present study an attempt is made to see with a naked eye examination through the Ayurvedic point of view. Cadaveric dissection was undertaken to find out if the regions were Acharya advised to do Tiryak Cheda can be supported with anatomical structures and their applied anatomy. Anatomical backgrounds of areas where Acharya has mentioned Tiryak Cheda was studied in detail.

The regions dissected were

Eyebrow, eyelid, forehead, temple, cheeks, lips, neck, gum, axilla, belly and groin region.

## OBSERVATION AND DISCUSSION

Acharya Sushruta has told that in eyebrows, cheeks, temples, forehead, eyelids, lips, gum, axila, belly and groin, Tiryak incision should be made. In hands and feet, one should make incisions like orb of moon while in anus and penis the same should be like half moon (semicircular).

The ideal incision should have the following characteristics:

- Easy to open.
- Minimize damage to tissues.
- Avoid cutting nerves.
- Split rather than transect muscles.
- Limit damage to fascia.
- Easy to close.
- Allow sufficiently strong closure.
- Allow sufficient access.
- Extendable if necessary.

### (i) Incisions over Bhru (Eyebrows) region

Acharya Sushruta has advised Tiryak incision at Bhru and modern surgery texts suggest slightly oblique incision (lateral eyebrow incision and superolateral incision). The oblique

incision placed here follows the RSTL and muscle fibres of orbital part of orbicularis oculi. It neither cut the branches of superficial temporal vein and artery nor to the branches of supraorbital nerve and of zygomaticotemporal nerve.

#### **(ii) Incisions over Ganda (Cheek) region**

In modern surgery texts only one incision i.e. Fergusson's incision which is the combination of vertical and horizontal incision.

When the neurovascular supply in the cheek region was checked in dissection, it was found that nearly all the neurovascular supply runs horizontally or obliquely. so giving Tiryak (oblique) incision in internervous space and intervascular space may be good decision and also this will follow the RSTL pattern.

#### **(iii) Incisions over Shankha (Temporal) region**

In the modern surgery texts, Gillies temporal incision was found which is of 2 cm length and directed upward and anteriorly at an oblique angle. It is placed in between the anterior and posterior divisions of superficial temporal artery with very little risk to part of zygomaticotemporal nerve. When the neurovascular supplies runs obliquely in this region. So making oblique incision in internervous and intervascular area will be safer and follow the RSTL pattern.

#### **(iv) Incisions over Lalata (Forehead) region**

Modern surgery refers for horizontal, vertical and zigzag type incisions over the forehead region (in bicoronal incision, midline vertical incision and 'w' shaped incision). The relaxed skin tension lines (RSTL) are in horizontal pattern on most of the forehead except over a small area above the base nose where these are in oblique manner.

On dissection it was found that on lateral side the branch of superficial temporal artery runs horizontally whereas in medial part the branches of supraorbital vein, supraorbital nerve, supratrochlear artery and supratrochlear nerve runs vertically. Thus in lateral part of forehead Tiryak incision is right but in medial part incision should be vertical.

#### **(v) Incisions over Akshiputa (Eyelid) region**

Modern surgery gives oblique incisions on eyelid in medial crease incision, upper lid incision (blepharoplasty), supratarsal incision, infraorbital subciliary approach and infraorbital

subpalpebral approach. In lateral canthotomy incision is horizontal. All these incisions follow the natural crease and the pattern of RSTL.

On dissection it was found that all the neurovascular structure running in upper and lower lids are in horizontal manner and the fibres of orbicularis oculi muscle also run horizontally. Thus horizontal and oblique incisions are best here and support to the Tiryak chedana.

#### **(vi) Incisions over Danta veshtaka (Gums)**

In the texts of maxillofacial and dental surgery a condition i.e. impacted teeth was found, in which horizontal incision over gums of molar and premolar teeth was given. In this incision the branches of lingual artery and inferior alveolar artery and nerve may be at risk.

#### **(vii) Incisions over the Gala (neck) and Jatru (clavicular) region**

In the texts of modern surgery it was found that all the incisions over neck 13 incisions were made horizontally over the neck. In dissection it was found that all the neurovascular structures in the neck pass vertically. The horizontal or oblique incision may produce greater risk of damage but the natural fold's crease and relaxed skin tension line run horizontally in circular mode. As the Tiryak indicate to horizontal or oblique, the incisions over neck used in modern surgery support to the instruction of Acharya Vagbhata.

#### **(viii) Incisions at Kaksha (Axilla) region**

In the texts of modern surgery, incision in deltopectoral approach of shoulder goes partly in axilla and it is a vertical incision by the definition of anatomical. The major structures at risk are, superiorly the acromial branch of thoracoacromial artery, inferiorly the musculocutaneous nerve, axillary nerve and cephalic vein. The modern surgery texts advise for giving the surgical incision either parallel to the relaxed skin tension lines or in natural crease. Here in axilla region both are the same so this incision gives better heal and cosmetic result.

#### **(ix) Incisions at Kukshi (Abdomen) region**

After referring to the incisions over anterior abdominal wall, it was found that the vertical incisions are used only in the median plane of abdomen. The reason behind this may be that in the anterior abdominal wall most of the neurovascular supply runs in oblique way from lateral to medial.



In transverse incisions, the upper abdominal transverse incision and lower abdominal transverse incision, both the rectus sheath and muscle are incised in horizontal plane.

On review of oblique incisions over abdomen (subcostal incision, chevron incision, Mercedes benz incision, grid iron incision and right or left lateral oblique Kocher incision) it was found that all these incisions placed in internervous and intervascular space produces least neurovascular injury. All the oblique incisions follow the RSTL and natural fold's crease over abdomen.

On the basis of anatomy, in context of neurovascular injury it can be said that the use of oblique incisions over abdomen are much safer in comparable to transverse incisions because after damage, the vascular supply may restore by anastomosing vessels but the nerve supply will never be regained.

#### (x) Incisions at Vankshana (groin) region

Acharya Sushruta has told the Tiryak incision in Vankshana (groin) region. The incisions of inguiofemoral area described in modern surgery texts are oblique. These are either parallel to inguinal ligament or curved in shape. These completely follow the RSTL and natural fold crease.

#### Region wise distribution of incisions in terms of directions

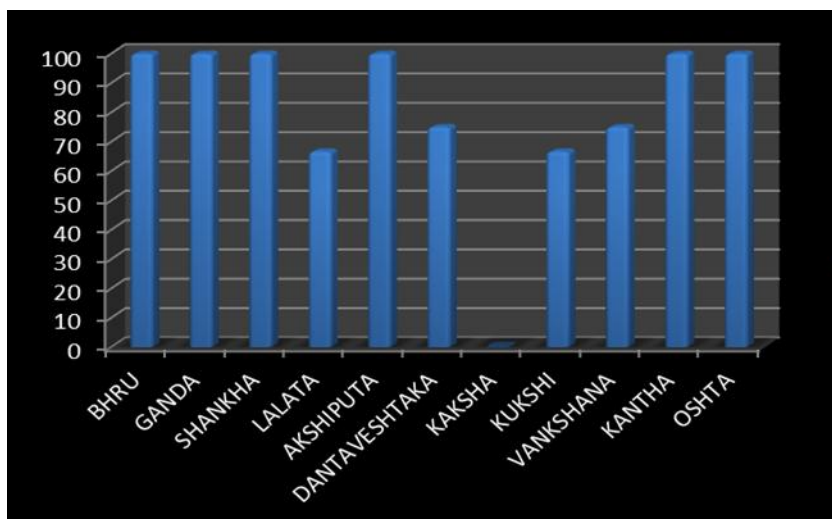
Name of the region	Total incisions	Vertical incision	Horizontal incision	Oblique incision
<i>Bhru</i> (eyebrow)	2	0	0	2
<i>Ganda</i> (cheeks)	2	0	0	2
<i>Shankha</i> (temple)	1	0	0	1
<i>Lalata</i> (forehead)	3	1	0	2
<i>Akshiputa</i> (eyelids)	6	0	1	5
<i>Dantaveshtaka</i> (gums)	4	1	3	0
<i>Kaksha</i> (axilla)	1	1	0	0
<i>Kukshi</i> (abdomen)	15	5	3	7
<i>Vankshana</i> (groins)	4	1	1	2
<i>Kantha</i> (neck)	17	0	16	1
<i>Oshtha</i> (lips)	1	0	0	1

#### Percentage of Tiryak Cheda in each region

Name of the region	Total incisions	Total <i>TIRYAK</i> incisions (horizontal/oblique)	Percentage of <i>TIRYAK</i> incisions
<i>Bhru</i> (eyebrow)	2	2	100
<i>Ganda</i> (cheeks)	2	2	100



<i>Shankha</i> (temple)	1	1	100
<i>Lalata</i> (forehead)	3	2	66.7
<i>Akshiputa</i> (eyelids)	6	6	100
<i>Dantaveshtaka</i> (gums)	4	3	75
<i>Kaksha</i> (axilla)	1	0	0
<i>Kukshi</i> (abdomen)	15	10	66.67
<i>Vankshana</i> (groins)	4	3	75
<i>Kantha</i> (neck)	17	17	100
<i>Oshta</i> (lips)	1	1	100



In Bhru, Ganda, Lalata, Akshiputa, Kantha and Oshta regions 100% of the incisions were found to be Tiryak, in Dantaveshtaka and Vankshana regions 75% of the incisions were Tiryak, in Lalata and Kukshi regions 66.67% of the incisions were Tiryak and in Kaksha region Tiryak incision accounted to zero percentage.

## RESULTS

In the instances where Acharya has described Tiryak chedana to be done, when we compare the modern incisions of those regions it is observed that;

- Of the two incisions done in Bhru region, both were oblique and hence Tiryak in nature.
- Of the two incisions in Ganda region, both were oblique and hence Tiryak in nature.
- The only incision described in Shankha region is curved and hence Tiryak in nature.
- Of the three incisions in Lalata region, two were found oblique and one vertical. Thus two out of three are Tiryak in nature.
- Of the six incisions in Akshiputa region one was horizontal and five oblique, thus all being Tiryak in nature.
- Of the four incisions described in Dantveshtaka three was horizontal and one vertical, hence three out of four are Tiryak in nature.

- The only incision in kaksha region was vertical and hence not Tiryak in nature. Thus no instance of Tiryak incision was found in this region.
- Of the fifteen incisions in Kukshi region, five were vertical, three horizontal and seven oblique. Thus ten out of fifteen are Tiryak in nature.
- Of the four incisions, one was vertical, one horizontal and two oblique in Vankshana region. Thus out of four three are Tiryak in nature.
- Of the seventeen incisions, four were oblique and thirteen horizontal in the Gala and Jatru region. Thus all being Tiryak in nature as said by Acharya Vagbhata.
- The only incision described in Oshtha region is oblique and hence Tiryak in nature as said by Acharya Vagbhata.

## CONCLUSION

- From the present study it can be concluded that there is significant relation between the Tiryak Cheda explained by Acharya Sushruta to the surgical incisions being practiced now.
- The incisions advised by Acharyas mostly follow the pattern of relaxed skin tension line and produces lesser damage of beneath structures.
- Planning a surgical incision requires considering many critical anatomical and logistical elements, all designed to afford safe and efficient mechanical exposure to the target of our efforts.
- Preserving deep and surrounding structures while taking into account the direction of the underlying muscles, critical neurovascular structures, and optimizing vascularity to healing structures is essential. Incisions for minimally invasive surgery should similarly follow these patterns of fold lines.
- The simplest rule for making incisions in the most favourable direction is to follow natural folding lines: “Proper incisions come together naturally and improper ones tend to gape.”

## REFERENCE

1. J.N.Mishra: Marma and its Management Vijnana; 5th Edition- Pub Chaukhamba Orientalia Varanasi, 2005; 69.
2. Jayanta Bhattacharya The Knowledge of Anatomy and Health in Āyurveda and Modern Medicine: Colonial Confrontation and Its Outcome by Jayanta Bhattacharya, 11.
3. Richard S. Snall. Clinical Anatomy by Region; Richard S. Snall 8th edition, 81.

4. Sushruta: Sushruta Samhita with Dalhana Commentary: Edited by Vaidya Jadavji Trikamji Acharya: Published by Chowkhamba Krishnadas Academy, Varanasi: Reprint, 2008; 20.
5. Sushruta: Sushruta Samhita with Dalhana Commentary: Edited by Vaidya Jadavji Trikamji Acharya: Published by Chowkhamba Krishnadas Academy, Varanasi: Reprint, 2008; 20.



# Case Report On Vataja Gridhrasi: An OPD Level Treatment Protocol

Dr. Deepa J G<sup>1</sup>, Dr Vijeeshmon K V<sup>1</sup>, Dr Eluri Venkateswara Reddy<sup>2</sup>

1. Assistant Professor, Department of Panchakarma, Sanskriti Ayurvedic Medical College and Hospital, Mathura
2. Professor and Head, Department of Panchakarma, Sanskriti Ayurvedic Medical College and Hospital, Mathura

## Abstract:

Gridhrasi explained in Ayurveda has symptoms of radiating pain from low back, thighs, calf to foot with or without heaviness, numbness and pulsating pain. Patient of 42 years having history of fall came with presenting complaint of radiating pain from low back to bilateral lower limbs. He got treated with external therapeutic procedures and internal palliative ayurveda medicines. The patient got symptomatic relief and improvement in range of motion.

Key words: Sciatica, Gridhrasi, Ayurveda, Panchakarma

Introduction: Lumbar radiculopathy is a condition in which pain is there in low back region and hip region which radiated down to thighs and up to foot. The radiating pain is mostly due to an impinged nerve among lumbar plexus. Impingement of nerve can be because of reduced space between lumbar vertebra or when too much pressure is applied on the nerve by the surrounding tissue like bone, cartilage or even herniated disc. Sometimes muscles or tendons can cause this condition. Pathologies can lead to compression of nerve tract are trauma, diabetes, arthritis, herniated disc, tumours, surgical complications, dislocated joints, hypothyroidism etc. It could be the result of haphazard life practices like over exercise, travelling, over weight etc. Sciatica is one among the largest nerve traversing to lower limb supplying to hamstring group if thigh muscles, to calf muscles along the back of the leg and continue downwards to outer component of ankle and heel. The tibial branch of this nerve is derived from L5, S1, S2 and S3 spinal nerves.

The symptoms will be affecting the particular dermatomes nerve roots are supplying. General symptoms include pins and needles, pain, numbness, burning or even loss of sensation in different parts of thighs, leg or foot. Motor part of sciatic nerve if affected may produce difficulty in movement of legs, muscle weakness, foot drop and eventually may lead to inability to walk. Diagnosis is with clinical examination and nerve conduction study, imaging techniques like MRI, USG and electromyography.

Conventional Treatment protocol starts with life style changes, medications like NSAIDs, steroids, physical therapy for releasing the pressure on impinged nerve. Surgical release of compression is also there.

Gridhrasi told in Ayurveda is in Vata vyadhi spectrum of diseases. The clinical presentation of the disease is of two types viz kevala vataja and vatakaphaja. In kevala vataja type there will pain starting from buttocks to thighs, knees, calf till foot is there. In vata kaphaja type apart from the radiating pain patient may also have drowsiness, anorexia and heaviness. Doshas like vata and kapha are involved in the aetiopathogenesis of this disease. Sthanasamsraya of these Doshas in Dushyas like asthi, mamsa, kandara, snayu and sira resulted in dushti of asthivaha, mamsavaha and raktavaha srotases. The vyadhi udbhava sthans is pakwasaya with adhishtana of Kati and sphik<sup>1</sup>. Srotodushti prakara is sanga. Hence the line of treatment for gridhrasi is told as vatahara chikitsa. This covers snehana, swedana and mridu sodhana.

Case Report: This male patient of 42 years walked in to the OPD with the complaint of low back ache which is radiating towards both lower limb. The patient seems well oriented and apparently well nourished started having the occasional episodes of low back since 6 months. Later the intensity and frequency of the pain increased and started affecting his daily chores. The pain aggravates after a bike ride or sitting or standing or walking for long and relieved only with lying down. The course of the pain also started radiating from low back to both legs and severely compromised his movements.

On clinical examination there was mild to moderate disc bulge seen at L5-S1 region with tenderness in paraspinal muscle, and of both legs. SLR test was positive with Right lower limb flexion is of 45-50 degree where as left limb showed flexion of 50-60 degree. Pain grading score was 10 before. Radiological examination reveals annular tear with asymmetrical disc bulge and postero-central protrusion of L5- S1 intervertebral disc. Right leg is more affected than left in MRI report also.

Diagnosis: Gridhrasi

Treatment: Protocol covers 1. Bahya Snehana Kriya – External snehana procedures include sarvanga abhyanga with Sahacharadi thailam, bashpa sweda with dasamoola kashaya, Kati basti with Sahacharadi and Mahanarayana thaila and Matra basti with Sahacharadi thaila for seven days. Externally one day Infra red radiation done for releasing the muscle spasm. Agnikarma done on seventh day with panchaloha shalaka at low back.

Shamana aushadhis given are Rasnasaptakam kwatham, Yogaraja Guggulu, Dhanwantharam 101 capsule, Dazzle BS tablet for seven days. Lumbagest was added as discharge medicine along with Rasnaerandadi Kwatha, Dazzle BS tablet, and Mahanarayana Thaila for external application for one month.

Result: Patient's pain was reduced from a VAS scale of 10 to 5 at the time of discharge and Range of motion of right leg and left leg got improved to 70 and 80 degrees respectively at the time of discharge. During follow up period of one month his pain got completely relieved and range of motion become normal with no associated complaints.

Discussion: Sciatica in modern medicine can be compared with Gridhrasi in Ayurveda. It's a vaataja nanatmaja vikara with very less involvement of other doshas. This patient also shows symptoms of kevala vata gridhrasi signs and symptoms with radiating pain from low back to foot. The treatment protocol for kevala vata says about snehana brmhana protocol<sup>iii</sup> and gridhrasi says about snehana, dahana and upanaha sweda<sup>iii</sup>. Here in this patient both the line of management was used by which both abhyantara and bahya snehana was given priority by effectively maintaining the agni of the patient. Abhyanga will reduce Vata<sup>iv</sup> which causes pain and Swedana will relieve stiffness, heaviness<sup>v</sup> of the joint which contribute to betterment of range of movement. Matra basti<sup>vi</sup> is helpful in correcting the apana vata which is situated in Pakwasaya the seat of Vata. Internal Medicine also are pachana at the same time capable of controlling this radiating type of pain of Gridhrasi. Rasnasaptakam kashayam is indicated for pain in hip, thigh, low back and general back and flank pain as well. Main ingredients in Rasnasaptak kwatha shows anti-inflammatory, analgesic and anti oxidant actions<sup>vii</sup>. Dhanwantharam 101 avarti thailam contains Bala ( Sida cordifolia) as the main ingredient which has antioxidant and adaptogenic property<sup>viii</sup> and may internally nourishes the joint space. Its beneficial for arthritic and neurological conditions. Yogaraja guggulu is effective in amavata, adyavata, sandhi majjagata vata vikara and udara<sup>ix</sup>. Mahanarayana thailam is told to be beneficial for shakhasrita and koshtasrita vata. It's meant for both internal as well as external use<sup>x</sup>. Agnikarma will give a sudden pain relief to patient by pain gate mechanism. Previous studyresukts showed thatagniosrma with panchaloha shalaka is capable of reducing pain in Gridhrasi patients<sup>xi</sup>. Hence all together this protocol can be considered even for an OPD level management for gridhrasi.

Conclusion:

Disease sciatica is the result of nerve entrapment and associated sympoms. Gridhrasi in Ayurveda with similar presentation can be managed with chikitsa sidhanta of gridhrasi and vata chikitsa. This case report is a proposal for OPD management of gridhrasi which cured the disease clinically.

## References

- <sup>i</sup> Agnivesha, Caraka Saṁhita, revised by Caraka and Dridhabala with the Āyurvēda Dipika commentary of Chakrapanidatta, edited by Vaidya Jadavaji Trikamji Acharya, Chaukhambha Prakashan, Varanasi, Reprint edition,2010, Chikitsa sthana, Chapter 28, Verse 56
- <sup>ii</sup> Vagbhata-Aṣṭāṅga Hṛdayam with commentaries Sarvangasundara of Srimat Arunadatta and Āyurvēdarasāyana of Hemadri, annotated by Dr. Anna Moreswar Kunde and Pt. Krishna Ramachandra Sastri Navre, Edited by Pt. Hari Sadasiva Sastri Paradakara, Chaukhamba Sanskrit Sansthan, Varanasi, Reprint 2009, Sutra sthana, Chapter 13 , Verse 1-2
- <sup>iii</sup> Agnivesha, Caraka Saṁhita, revised by Caraka and Dridhabala with the Āyurvēda Dipika commentary of Chakrapanidatta, edited by Vaidya Jadavaji Trikamji Acharya, Chaukhambha Prakashan, Varanasi, Reprint edition,2010, Chikitsa sthana, Chapter 28, Verse 100-101
- <sup>iv</sup> Vagbhata-Aṣṭāṅga Hṛdayam with commentaries Sarvangasundara of Srimat Arunadatta and Āyurvēdarasāyana of Hemadri, annotated by Dr. Anna Moreswar Kunde and Pt. Krishna Ramachandra Sastri Navre, Edited by Pt. Hari Sadasiva Sastri Paradakara, Chaukhamba Sanskrit Sansthan, Varanasi, Reprint 2009, Sutra sthana, Chapter 2, Verse 8
- <sup>v</sup> Agnivesha, Caraka Saṁhita, revised by Caraka and Dridhabala with the Āyurvēda Dipika commentary of Chakrapanidatta, edited by Vaidya Jadavaji Trikamji Acharya, Chaukhambha Prakashan, Varanasi, Reprint edition,2010, Sutra sthana, Chapter 14, Verse 23
- <sup>vi</sup> Vagbhata-Aṣṭāṅga Hṛdayam with commentaries Sarvangasundara of Srimat Arunadatta and Āyurvēdarasāyana of Hemadri, annotated by Dr. Anna Moreswar Kunde and Pt. Krishna Ramachandra Sastri Navre, Edited by Pt. Hari Sadasiva Sastri Paradakara, Chaukhamba Sanskrit Sansthan, Varanasi, Reprint 2009, Sutra sthana, Chapter 19, Verse 68-69
- <sup>vii</sup> Shruti Pandey, Anand Kumar Chaudhary, A review on Rasna saptak kwath: An Ayurvedic polyherbal formulation for arthritis, Int J. Res. Ayurveda Pharm. B (Suppl 1),2017
- <sup>viii</sup> K. Dhalwal, Y.S. Deshpande, A.P. Purohit & S.S. Kadam (2005) Evaluation of the Antioxidant Activity of Sida cordifolia., Pharmaceutical Biology, 43:9, 754-761, DOI: 10.1080/13880200500406438
- <sup>ix</sup> Govindadasa Sena, Bhaishajya ratnavali, Hindi Teeka,Chapter Amavata, Verse 29/153-161
- <sup>x</sup> Govindadasa Sena, Bhaishajya ratnavali, Hindi Teeka, Chapter Vata vyadhi, Verse 151-162
- <sup>xi</sup> Babita Bakhshi, S K Gupta et.al. , A comparative study of Agni karma with Lauha, Tamra and Panchadhatu shalaka in Gridhrasi( Sciatica), Ayu.2010, Apr-Jun; 31(2):240-244





# “A COMPREHENSIVE STUDY OF SURGICAL INCISIONS WITH SPECIAL REFERENCE TO TIRYAK CHEDA AND ITS APPLIED ANATOMY”

Dr. E.R.Surabhi\*

## ABSTRACT

*Acharya Sushruta* has described *Astavidha Shastrakarmas*, incisions being one among them. The type of incisions according to region has also been described. *Chedana* should be *Tiryak* at *Bhru* (eyebrow), *Ganda* (cheek), *Shankha* (temple), *Lalata* (forehead), *Akshiputa* (eyelid), *Ostha* (lip), *Dantaveshtaka* (gum), *Kaksha* (axilla), *Kukshi* (belly) and *Vankshana* (groin) region. Otherwise there is cutting of veins and ligaments, severe pain, delayed healing and appearance of polypus-like growth.

The understanding of *Tiryak Chedana* is still vague and needs to be studied in depth. There are various types of surgical incisions indicated in modern surgery. So in light of Ayurvedic and Modern references the surgical incisions in the regions were *Tiryak Cheda* has been advised by *Acharyas* were compared and assessed along with cadaveric dissection of these regions.

From the present study it was observed that there is significant relation between the *Tiryak Cheda* explained by *Sushruta* to the surgical incisions being practiced now. The incisions advised by *Acharyas* mostly follow the pattern of relaxed skin tension line and produces lesser damage of beneath structures

Key Words: *Tiryak Cheda*, surgical incisions, dissection.

## INTRODUCTION

The history of trauma can be anticipated from the date, survival of the fittest. The surgical experience of the ancient age has been compiled systematically in *Sushruta Samhita*, which is a first documentation of its kind.<sup>1</sup>

Defining the anatomical site of the lesion is crucial if the physician is to resolve the problem effectively and compassionately. Therefore, a sound knowledge of anatomy is essential from the beginning of a modern medical education. The singular act of cadaveric dissection in Indian medical curricula brought about changes in the perception of body, health and illness.<sup>2</sup>



“Surgical incision is a cut in to body tissue or organ made during surgery with sharp instrument.”

Incision must not only give ready and direct access to the anatomy to be investigated but also provide sufficient room for operation to be performed with minimum damage of constituent structures. An incision along the cleavage line will heal as a narrow scar, whereas one that crosses the line will heal as wide or heaped up scar.<sup>3</sup>

Acharya Sushruta has indicated types of incisions according to region for Bhedana karma and also clearly described the reason behind it.<sup>4,5</sup>

There are various types of surgical incisions indicated in modern surgery, so in light of most advanced knowledge of anatomy, region wise comparative study of the incisions of both the science was done and also a trial was made to emphasize the uses of ancient knowledge today.

## **MATERIALS AND METHODS**

Literary data were collected from, different classical texts, journals, internet, previous Thesis works etc.

Study was done to analyse the anatomical background of the regions where *Tiryak Cheda* has been mentioned by *Acharyas*.

Cadaver data was collected from dissection of 5 cadavers, carried out in the dissection hall of Alvas Ayurveda College, Moodbidri.

## **METHODOLOGY**

- Dissections of 5 cadavers were carried out
- Observations of underlying anatomical structures of each of the regions were *Acharyas* has advised *Tiryak Cheda* was done.
- Collected data was analyzed and discussed emphatically.

Structurally well prepared and preserved cadavers were selected.

## **PROCEDURE**

Detailed dissection of 5 cadavers was carried out.. The cadavers were 5 male subjects, with an estimated age range of 56 to 80 years. All cadavers were preserved in a standard formalin/phenol/alcohol solution and routinely dissected under guidance. The dissection procedures were carried out as per Cunningham’s Manual of Practical Anatomy.

In the present study an attempt is made to see with a naked eye examination through the Ayurvedic point of view. Cadaveric dissection was undertaken to find out if the regions were Acharya advised to do Tiryak Cheda can be supported with anatomical structures and their applied anatomy. Anatomical backgrounds of areas where Acharya has mentioned Tiryak Cheda was studied in detail

The regions dissected were:

Eyebrow, eyelid, forehead, temple, cheeks, lips, neck, gum, axilla, belly and groin region.

## OBSERVATION AND DISCUSSION

Acharya Sushruta has told that in eyebrows, cheeks, temples, forehead, eyelids, lips, gum, axilla, belly and groin, Tiryak incision should be made. In hands and feet, one should make incisions like orb of moon while in anus and penis the same should be like half moon (semicircular).

The ideal incision should have the following characteristics:

- Easy to open.
- Minimize damage to tissues.
- Avoid cutting nerves.
- Split rather than transect muscles.
- Limit damage to fascia.
- Easy to close.
- Allow sufficiently strong closure.
- Allow sufficient access.
- Extendable if necessary.

### (i) Incisions over Bhru (Eyebrows) region:

Acharya Sushruta has advised Tiryak incision at Bhru and modern surgery texts suggest slightly oblique incision (lateral eyebrow incision and superolateral incision). The oblique incision placed here follows the RSTL and muscle fibres of orbital part of orbicularis oculi. It neither cut the branches of superficial temporal vein and artery nor to the branches of supraorbital nerve and of zygomaticotemporal nerve.

### (ii) Incisions over Ganda (Cheek) region:

In modern surgery texts only one incision i.e. Fergusson's incision which is the combination of vertical and horizontal incision.

When the neurovascular supply in the cheek region was checked in dissection, it was found that nearly all the neurovascular supply runs horizontally or obliquely. So giving Tiryak (oblique) incision in internervous space and intervacular space may be good decision and also this will follow the RSTL pattern.

### (iii) Incisions over Shankha (Temporal) region:

In the modern surgery texts, Gillies temporal incision was found which is of 2 cm length and directed upward and anteriorly at an oblique angle. It is placed in between the anterior and posterior diversions of

superficial temporal artery with very little risk to part of zygomatico temporal nerve. When the neurovascular supplies runs obliquely in this region. So making oblique incision in internervous and intervascular area will be safer and follow the RSTL pattern.

**(iv) Incisions over Lalata (Forehead) region:**

Modern surgery refers for horizontal, vertical and zigzag type incisions over the forehead region (in bicoronal incision, midline vertical incision and 'w' shaped incision). The relaxed skin tension lines (RSTL) are in horizontal pattern on most of the forehead except over a small area above the base nose where these are in oblique manner.

On dissection it was found that on lateral side the branch of superficial temporal artery runs horizontally whereas in medial part the branches of supraorbital vein, supraorbital nerve, supratrochlear artery and supratrochlear nerve runs vertically. Thus in lateral part of forehead Tiryak incision is right but in medial part incision should be vertical.

**(v) Incisions over Akshiputa (Eyelid) region:**

Modern surgery gives oblique incisions on eyelid in medial crease incision, upper lid incision (blepharoplasty), supratarsal incision, infraorbital subciliary approach and infraorbital subpalpebral approach. In lateral canthotomy incision is horizontal. All these incisions follow the natural crease and the pattern of RSTL.

On dissection it was found that all the neurovascular structure running in upper and lower lids are in horizontal manner and the fibres of orbicularis oculi muscle also run horizontally. Thus horizontal and oblique incisions are best here and support to the Tiryak chedana.

**(vi) Incisions over Danta veshtaka (Gums):**

In the texts of maxillofacial and dental surgery a condition i.e. impacted teeth was found, in which horizontal incision over gums of molar and premolar teeth was given. In this incision the branches of lingual artery and inferior alveolar artery and nerve may be at risk.

**(vii) Incisions over the Gala (neck) and Jatru (clavicular) region:**

In the texts of modern surgery it was found that all the incisions over neck 13 incisions were made horizontally over the neck In dissection it was found that all the neurovascular structures in the neck pass vertically. The horizontal or oblique incision may produce greater risk of damage but the natural fold's crease and relaxed skin tension line run horizontally in circular mode. As the Tiryak indicate to horizontal or oblique, the incisions over neck used in modern surgery support to the instruction of Acharya Vagbhata.

**(viii) Incisions at Kaksha (Axilla) region:**

In the texts of modern surgery, incision in deltopectoral approach of shoulder goes partly in axilla and it is a vertical incision by the definition of anatomical. The major structures at risk are, superiorly the acromial branch of thoracoacromial artery, inferiorly the musculocutaneous nerve, axillary nerve and cephalic vein. The modern surgery texts advise for giving the surgical incision either parallel to the relaxed skin tension lines or in natural crease. Here in axilla region both are the same so this incision gives better heal and cosmetic result.

**(ix) Incisions at Kukshi (Abdomen) region:**

After referring to the incisions over anterior abdominal wall, it was found that the vertical incisions are used only in the median plane of abdomen. The reason behind this may be that in the anterior abdominal wall most of the neurovascular supply runs in oblique way from lateral to medial.

In transverse incisions, the upper abdominal transverse incision and lower abdominal transverse incision, both the rectus sheath and muscle are incised in horizontal plane.

On review of oblique incisions over abdomen (subcostal incision, chevron incision, Mercedes benz incision, grid iron incision and right or left lateral oblique Kocher incision) it was found that all these incisions placed in internervous and intervascular space produces least neurovascular injury. All the oblique incisions follow the RSTL and natural fold's crease over abdomen.

On the basis of anatomy, in context of neurovascular injury it can be said that the use of oblique incisions over abdomen are much safer in comparable to transverse incisions because after damage, the vascular supply may restore by anastomosing vessels but the nerve supply will never be regained.

**(x) Incisions at Vankshana (groin) region:**

Acharya Sushruta has told the Tiryak incision in Vankshana (groin) region. The incisions of inguofemoral area described in modern surgery texts are oblique. These are either parallel to inguinal ligament or curved in shape. These completely follow the RSTL and natural fold crease.

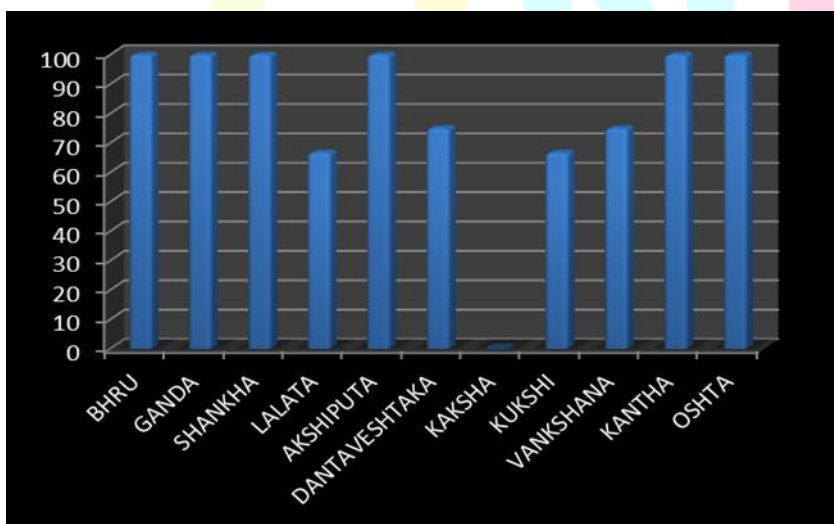
**Region wise distribution of incisions in terms of directions:**

Name of the region	Total incisions	Vertical incision	Horizontal incision	Oblique incision
<i>Bhru</i> (eyebrow)	2	0	0	2
<i>Ganda</i> (cheeks)	2	0	0	2
<i>Shankha</i> (temple)	1	0	0	1
<i>Lalata</i> (forehead)	3	1	0	2
<i>Akshiputa</i> (eyelids)	6	0	1	5
<i>Dantaveshtaka</i> (gums)	4	1	3	0

<i>Kaksha</i> (axilla)	1	1	0	0
<i>Kukshi</i> (abdomen)	15	5	3	7
<i>Vankshana</i> (groins)	4	1	1	2
<i>Kantha</i> (neck)	17	0	16	1
<i>Oshta</i> (lips)	1	0	0	1

### Percentage of Tiryak Cheda in each region:

Name of the region	Total incisions	Total incisions (horizontal/oblique)	<i>TIRYAK</i>	Percentage of <i>TIRYAK</i> incisions
<i>Bhru</i> (eyebrow)	2	2		100
<i>Ganda</i> (cheeks)	2	2		100
<i>Shankha</i> (temple)	1	1		100
<i>Lalata</i> (forehead)	3	2		66.7
<i>Akshiputa</i> (eyelids)	6	6		100
<i>Dantaveshtaka</i> (gums)	4	3		75
<i>Kaksha</i> (axilla)	1	0		0
<i>Kukshi</i> (abdomen)	15	10		66.67
<i>Vankshana</i> (groins)	4	3		75
<i>Kantha</i> (neck)	17	17		100
<i>Oshta</i> (lips)	1	1		100



In Bhru, Ganda, Lalata, Akshiputa, Kantha and Oshta regions 100% of the incisions were found to be Tiryak, in Dantaveshtaka and Vankshana regions 75% of the incisions were Tiryak, in Lalata and Kukshi



regions 66.67% of the incisions where Tiryak and in Kaksha region Tiryak incision accounted to zero percentage.

## RESULTS:

In the instances where Acharya has described Tiryak chedana to be done, when we compare the modern incisions of those regions it is observed that;

- Of the two incisions done in Bhru region, both were oblique and hence Tiryak in nature.
- Of the two incisions in Ganda region, both were oblique and hence Tiryak in nature.
- The only incision described in Shankha region is curved and hence Tiryak in nature.
- Of the three incisions in Lalata region, two were found oblique and one vertical. Thus two out of three are Tiryak in nature.
- Of the six incisions in Akshiputa region one was horizontal and five oblique, thus all being Tiryak in nature.
- Of the four incisions described in Dantveshtaka three was horizontal and one vertical, hence three out of four are Tiryak in nature.
- The only incision in kaksha region was vertical and hence not Tiryak in nature. Thus no instance of Tiryak incision was found in this region.
- Of the fifteen incisions in Kukshi region, five were vertical, three horizontal and seven oblique. Thus ten out of fifteen are Tiryak in nature.
- Of the four incisions, one was vertical, one horizontal and two oblique in Vankshana region. Thus out of four three are Tiryak in nature.
- Of the seventeen incisions, four were oblique and thirteen horizontal in the Gala and Jatru region. Thus all being Tiryak in nature as said by Acharya Vagbhata.
- The only incision described in Oshtha region is oblique and hence Tiryak in nature as said by Acharya Vagbhata.

## CONCLUSION

- From the present study it can be concluded that there is significant relation between the Tiryak Cheda explained by Acharya Sushruta to the surgical incisions being practiced now.
- The incisions advised by Acharyas mostly follow the pattern of relaxed skin tension line and produces lesser damage of beneath structures.
- Planning a surgical incision requires considering many critical anatomical and logistical elements, all designed to afford safe and efficient mechanical exposure to the target of our efforts.

•Preserving deep and surrounding structures while taking into account the direction of the underlying muscles, critical neurovascular structures, and optimizing vascularity to healing structures is essential. Incisions for minimally invasive surgery should similarly follow these patterns of fold lines.

•The simplest rule for making incisions in the most favourable direction is to follow natural folding lines: “Proper incisions come together naturally and improper ones tend to gape.”

## REFERENCE

1.J.N.Mishra: Marma and its Management Vijnana;5th Edition-2005;Pub Chaukhamba Orientalia Varanasi;page no: 69

2. Jayanta Bhattacharya .The Knowledge of Anatomy and Health in Āyurveda and Modern Medicine: Colonial Confrontation and Its Outcome by Jayanta Bhattacharya: page no:11

3..Richard S. Snall. Clinical Anatomy by Region; Richard S. Snall 8th edition page no:81

4.Sushruta: Sushruta Samhita with Dalhana Commentary: Edited by Vaidya Jadavji Trikamji Acharya: Published by Chowkhamba Krishnadas Academy, Varanasi: Reprint 2008: page no: 20

5.Sushruta: Sushruta Samhita with Dalhana Commentary: Edited by Vaidya Jadavji Trikamji Acharya: Published by Chowkhamba Krishnadas Academy, Varanasi: Reprint 2008: page no:20

